

# Tacrolimus Ointment

## Effectiveness and Safety of Tacrolimus in Vitiligo Children

Padmaleela <sup>a</sup>, Dr.P.Venkatesh <sup>b</sup>, Dr.D.Hepcykalarini <sup>c</sup>, Dr.R.Prema<sup>d</sup>.

Email:saranayashannu1920@gmail.com

Institution Name: Jagan's intuitions of pharmaceutical sciences  
Jangalakandriga Muthukur, Nellore(Dist.), Andhra Pradesh.

**Abstract:** Thus far, several small studies and case reports on the use of topical immunomodulators in vitiligo have been published. We undertook a comprehensive literature review, searching for studies evaluating clinical response to tacrolimus topical therapy for vitiligo. Our inclusion criteria were: Use of tacrolimus ointment as monotherapy to treat vitiligo. We found 29 studies from 2002 to 2014. Overall, 709 patients were treated in 29 studies. Pooling the lesions, 50% repigmentation of vitiligo patches was never achieved before 2 months of treatment, with a peak after 6 months of therapy. The best results were obtained on lesions of the cephalic region, especially the face, with tacrolimus 0.1% ointment two times daily. The percentage of non-responsive patients ranged from 0% to 14%. The lack of melanin pigment makes the lesional skin more sensitive to sunburn. Vitiligo can be cosmetically disfiguring and is a stigmatizing condition, leading to serious psychological problems in daily life. It occurs worldwide in about 1% of the population, mostly between the ages of 10-30 years, and as often in males as in females. The cause is unknown, but might involve genetic factors, autoimmunity, toxic metabolites, and/or a higher vulnerability of melanocytes. Some new treatments for this condition include corticosteroid + UVA treatment, UVB narrow wave band (311nm) irradiation, and transplantation of autologous pigment cells. In widespread Vitiligo, residual pigment can be removed by depigmentation agents. Sunscreens, camouflage products and good guidance may help the patient to better cope with this disease.

**Keywords:** Ointment, Vitiligo, Monotherapy, Immunomodulators, Topical Application.

**INTRODUCTION :** Vitiligo is characterized by the progressive disappearance of melanocytes, resulting in depigmentation of the skin and/or hair. It is an acquired depigmentation disorder with challenging management. Usually, it takes several months or years for noticeable repigmentation. The therapeutic options depend on vitiligo type and disease severity. The etiology of vitiligo is unknown.

Genetic studies support a non-mendelian inheritance, suggesting that vitiligo is a multifactorial, polygenic disorder. The autoimmune theory remains the most widely accepted. It has frequently been reported in association with autoimmune disorders such as thyroid disease, diabetes mellitus and alopecia areata.

Vitiligo is characterized by achromatic spots related to the loss of melanocytes in the epidermis and the hair follicle. It happens at any age, affects both sexes and in some regions, affects up to 2% of the population. It influences considerably the quality of life of the patients. None of the therapeutic alternatives is fully satisfactory either because its improvement is unpredictable and the treatment is long or because of the side effects and operational difficulty of application of the medication.

Topical corticosteroids remain the standard treatment .however sideeffects from long term applications of corticosteroids, which induce skin atrophy and telangiectasia,are of major concern .the use of topical tacrolimus, a topical calcineurin inhibitor, in vitiligo was first reported in2002. It is an immunomodulator that affects activation and maturation of t cells, including enhancement of melanocyte migration and differentiation ,which effects its effect on repigmentation of vitiligo.

In the past 13 years, the efficacy of topical tacrolimus in the treatment of childhood and adult vitiligo has been reported. 2,3,4 mometasone furoate is a nonfluorinated class iv corticosteroid with a good safety profile. It has a much greater vasoconstriction property than hydrocortisones, but similar adverse effects. Mometasone furoate 0.1% demonstrated excellent efficacy in the treatment of childhood vitiligo. For adult vitiligo, mometasone is generally prescribed by physicians; however, the data of its efficacy in vitiligo are still lacking. Herein, the authors reported the outcome of a comparison study using 0.1% mometasone furoate cream for adult vitiligo vulgaris in terms of their efficacy and safety profiles.

Treatment of this disease is divided to medication and surgery. Medication also included two types of topical and systemic split. Topical treatments include topical steroids, intralesional steroids, tacrolimus, calcipotriol topical, topical psoralen ultraviolet a (puva). Systemic treatments include systemic steroids and systemic puv. None of the above therapies are not considered as first-line treatment method, but therapeutic approaches is depended to the condition of patient.

### DEFINITION OF VITILIGO :

A condition in which the skin turns white due to the loss of pigment from the melanocytes, cells that produce the pigment melanin that gives the skin color. In vitiligo, the melanocytes are destroyed, leaving depigmented patches of skin. The hair that

grows in areas affected by vitiligo may also turn white. The skin is not otherwise damaged. People with vitiligo must protect their skin from exposure to the sun. Also known as piebald skin and acquired leukoderma.



Image: Asian with Vitiligo

## **TYPES OF VTILIGO:**

### **1. Segmental Vitiligo:**

Affects one segment, or side, of the body (a hand, a leg, or the face) and in 50% of individuals some hair (on head, eyebrows, eyelashes). Symptoms appear at an early age and progress for only a few years.

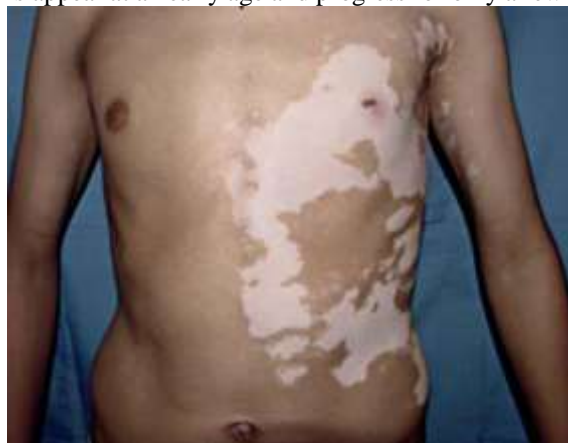


Image: Person body with Segmental Vitiligo

### **2. Non-Segmental Vitiligo:**

It is more common and affects both sides of the body. It usually begins with a short-lived burst of discoloration on the hands, feet, or face. The affected areas expand with new cycles of pigment loss that occur throughout the person's life.

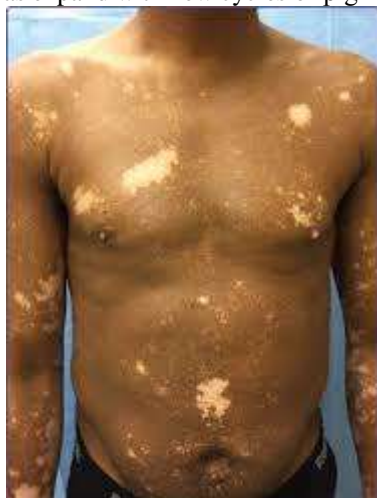
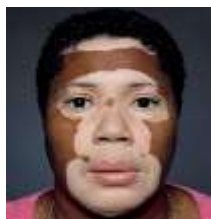
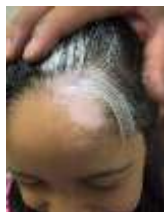Image: Person body with Non-Segmental Vitiligo

## **SYMPTOMS OF VITILIGO:**

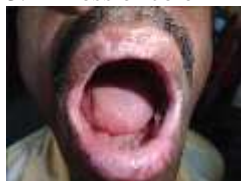1. Patchy loss of skin color



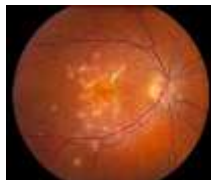2. Premature whitening or graying of the hair on your scalp, eyelashes, eyebrows or beard



3. Loss of color in the tissues that line the inside of your mouth and nose (mucous membranes).



4. Loss of or change in color of the inner layer of the eyeball (retina).



#### METHODS:

This was a clinical trial with pre-and post-test design method. the study has been conducted on vitiligo patients have referred to polyclinic and dermatology part of Au Ali Sina hospital, Sari, Mazandaran (2013–2014).

To verify the effectiveness of Tacrolimus alone, we selected studies that discussed Tacrolimus ointment as monotherapy for Vitiligo treatment.

A literature search on medline/pubmed was performed for articles evaluating clinical response using Tacrolimus as topical therapy for vitiligo. the keywords were: "Vitiligo" combined with "topical" and "ointment". literature search on medline/pubmed was performed for articles evaluating clinical response using tacrolimus as topical therapy for vitiligo. the keywords were: "vitiligo" combined with "topical" and "ointment".

Inclusion criteria were: 1) case study, review of literature, case report, clinical trial, open-label prospective study 2) Tacrolimus used as Monotherapy. the exclusion criterion was tacrolimus as a combination therapy.

The entire pubmed database was explored, without time restrictions. each article was tabulated as follows: authors, year of study, type of study, number of patients, age (in years) and sex of patients, localization of disease, treatment protocol, adverse effects, outcome.

Studies discussing children and adults were included, along with studies describing topical treatment with both tacrolimus ointment 0.03% and tacrolimus ointment 0.1% . English and non-english-language papers were included.

**THERAPEUTIC EFFECT:** The mainstays of vitiligo therapy in children and adults are topical corticosteroids and phototherapy.<sup>1,2</sup> None of the 3 patients herein responded to midpotency topical corticosteroid therapy after a 3- to 4-month trial. Eyelid and facial skin is thin, and high-potency topical corticosteroids may cause atrophy, dyspigmentation, telangiectasias, and glaucoma if used for an extended period.

Thus far, several small studies and case reports on the use of topical immunomodulators in vitiligo have been published. We undertook a comprehensive literature review, searching for studies evaluating clinical response to tacrolimus topical therapy for vitiligo. A search was performed on PubMed/Medline using the term "vitiligo", combined with "topical" and "ointment". Our inclusion criteria were: use of tacrolimus ointment as monotherapy to treat vitiligo. We found 29 studies from 2002 to 2014. Overall, 709 patients were treated in 29 studies. Pooling the lesions, 50% repigmentation of vitiligo patches was never achieved before 2 months of treatment, with a peak after 6 months of therapy. The best results were obtained on lesions of the cephalic region, especially the face, with tacrolimus 0.1% ointment two times daily. The percentage of non-responsive patients ranged from 0% to 14%. Treatment was generally well-tolerated; only localized adverse effects were reported. Our objective was to verify the effectiveness and safety of tacrolimus ointment monotherapy. It has good efficacy and tolerability. At present, only

small trials and case series are available in the literature. Further, standardized investigations on a larger number of patients are needed.

**STATISTICAL ANALYSIS:** All statistical calculations were performed by the statistical software package SPSS, version 17.0 (SPSS Inc., Chicago, IL, USA). The grading of improvements by two dermatologists was subjected to inter-rated reliability assessment and paired sample t test. Descriptive statistics were assessed using the Chi-square test.

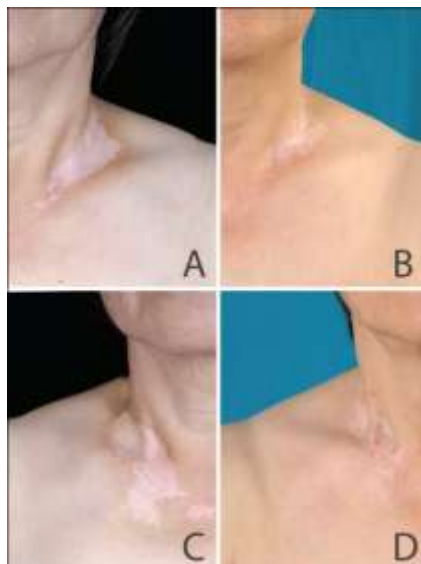

Image: Tacrolimus-treated side at (A) baseline and (B) 6 months' follow-up. Mometasone furoate cream-treated side at (C) baseline and (D) 6 months' follow-up.

**RESULTS:** Eighteen participants completed the study. Two dropped out because of inconveniences in the follow-up schedule. Demographic data including those of age, gender, duration of vitiligo, treated location, underlying diseases, and repigmentation outcome are given in Table 1. In the tacrolimus group, successful repigmentation (> 50%) was demonstrated in 22%, with 11% achieving > 75% repigmentation, while ~50% of cases showed 1–25% repigmentation. In the mometasone group, 33% of cases gained successful repigmentation, with 11% achieving > 75% repigmentation, while 33% of cases had 1–25% repigmentation. There was no statistically significant difference in the grading of repigmentation in both groups ( $p = 0.13$ ); however, repigmentation of lesions on the mometasone-treated side was achieved earlier. At 2 months, repigmentation was seen in eight cases on the mometasone-treated side and in three cases on the tacrolimus-treated side (Figure 1). There was an agreement of grading improvement evaluated by two independent dermatologists using inter-rated reliability assessment. With respect to the location, a higher percentage of repigmentation in both groups was achieved on the neck, followed by on the trunk and extremities. At the end of the study, telangiectasia was found in six cases on the mometasone-treated sites, while no case of telangiectasia was observed on the tacrolimus-treated side ( $p = 0.03$ ). No striae or skin atrophy was detected in both groups. Eight (44.4%) cases and five (27.7%) cases reported slight burning and stinging sensation on the tacrolimus- and mometasone-treated sides, respectively. However, both agents were well tolerated by these patients.

**Table 1: Characteristics of the 18 vitiligo patients.**

Variable	Data (n = 18)
<b>Age (y)</b>	
Mean $\pm$ SD	46.8 $\pm$ 15.60
<b>Gender</b>	
Male:Female	1:17
<b>Duration of vitiligo (mo)</b>	
Mean $\pm$ SD	25 $\pm$ 18
<b>Underlying Disease (n)</b>	
Hypothyroidism	3
Diabetes Mellitus	1
<b>Treated location (n) for each group</b>	
Neck	6

Trunk	4
Axilla	4
Wrist	3
Knee	1

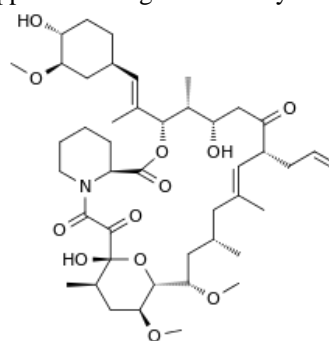
Repigmentation (Tacrolimus group) (n)	None	1-25%	26-50%	51-75%	76-100%
Neck (6)	2	1	1	1	1
Trunk (4)		3		1	
Axilla (4)		4			
Wrist (3)	1	2			
Knee (1)					1

Repigmentation	None	1-25%	26-50%	51-75%	76-100%
Neck (6)	2		1	2	1
Trunk (4)		2		2	
Axilla (4)	1	2	1		
Wrist (3)		1	2		
Knee (1)					1

SD = standard deviation

**TACROLIMUS DATA:** Tacrolimus was discovered in 1987, it was among the first macrolide immunosuppressants discovered, preceded by the discovery of rapamycin (sirolimus) on Rapa Nui (Easter Island) in 1975. It is produced by a soil bacterium, *Streptomyces tsukubaensis*. The name tacrolimus is derived from "Tsukuba macrolide immunosuppressant".

Tacrolimus, also known as 'Fujimycin' or 'FK506', is an immunosuppressive drug used mainly after allogeneic organ



transplant to lower the risk of organ rejection

Image: Clinical data of Tacrolimus

- Tacrolimus was first approved by the Food and Drug Administration in 1994 for use in liver transplantation; this has been extended to include kidney, heart, small bowel, pancreas, lung, trachea, skin, cornea, bone marrow limb transplants, and the skin condition Vitiligo.

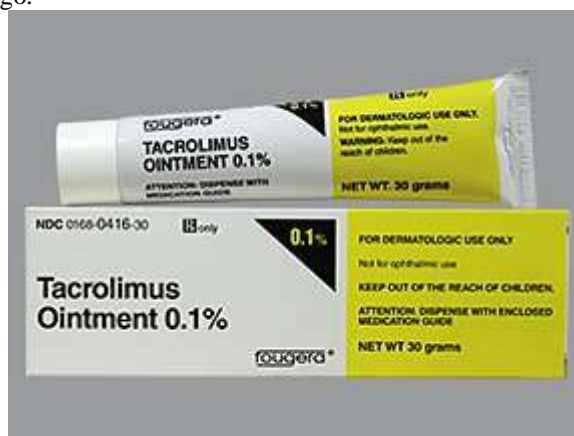

Image: Tacrolimus Ointment 0.1%



## EFFECTIVENESS OF TACROLIMUS:

### CASE STUDY 1 :

A prospective study was conducted by the Pharmacology department from October 2005 to September 2006. Sixty-three patients diagnosed as localized vitiligo by the dermatologist at R.L. Jalappa Hospital and Research Centre attached to Sri Devaraj Urs Medical College, Kolar, were included in the study. Informed consent was taken from all the patients. Ethical clearance was obtained from the institutional ethical committee.

The improvement in VASI score represents the repigmentation of vitiligo lesions which was statistically significant as observed in other studies. Good response observed in patients having lesions involving the face (eyelids, around the ear, and the post auricular region) may be due to greater density of hair follicles in these areas and thus the greater melanocyte reservoir.

Most common therapy in vitiligo involving <10% of the body surface area is with topical steroids. Clinical response and the repigmentation with topical steroids are almost similar to that of topical tacrolimus. Steroid application causes atrophy of skin, telangiectasia, hypertrichosis and acne, but these are not seen with tacrolimus treatment.

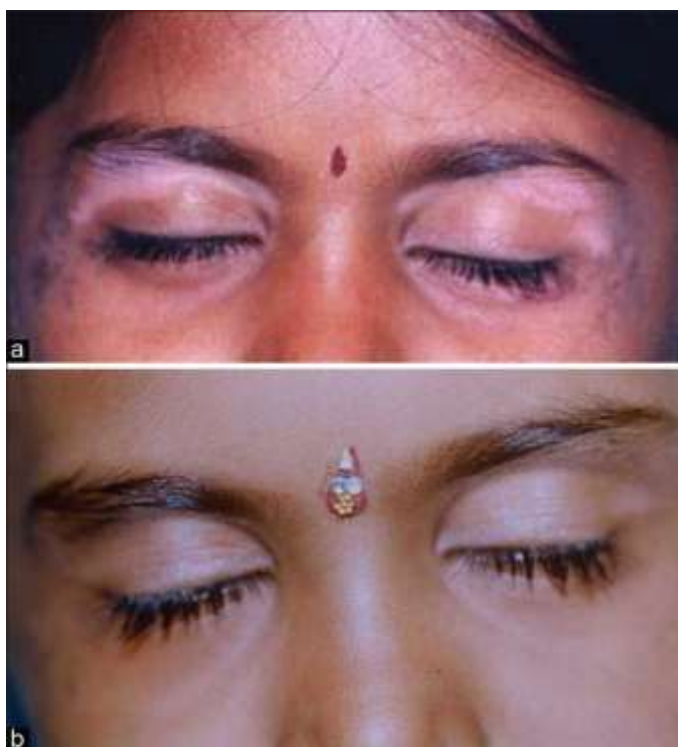

Image: a is before treatment  
b is after Treatment

### CASE STUDY 2:

A 23-year-old Hispanic woman with Fitzpatrick type IV skin presented with vitiligo vulgaris affecting 75% of her face, including complete depigmentation of the eyelids, chin, cheeks, and perioral skin. As is the standard practice of our vitiligo clinic, thyroid function testing, blood cell counts, and vitamin B12 levels were taken; all were within normal limits. Mometasone furoate ointment was applied twice daily for 3 months with no signs of follicular repigmentation either on visual examination or with the use of the Wood light.

### CASE STUDY 3:

A 24-year-old man with Fitzpatrick type II skin presented with a history of vitiligo vulgaris for 12 years. At the time of presentation, he had depigmentation of 60% of his body surface area, including the eyelids, chin, axillae, elbows, hips, knees, and back. Thyroid function findings, blood cell counts, and vitamin B12 levels were all within normal limits. Topical mometasone furoate cream was applied to the eyelids twice daily for 4 months, during which the patient also underwent a course of narrowband UV-B irradiation to the entire body.

### CASE STUDY 4:

A 10-year-old African American boy with Fitzpatrick type VI skin had a history of microcephaly, absence of the radii bilaterally, and learning disabilities. Eight months prior to presentation, he began to develop rapid depigmentation of the forehead, forearms, chest, back, and calves. Thyroid function findings, blood cell counts, and vitamin B12 levels were all within normal limits. Triamcinolone acetonide ointment (0.1%) was tried for 3 months with no repigmentation.

#### **SAFETY WITH TACROLIMUS:**

The most common adverse events were related to local irritation; these were burning sensation, pruritus, and skin erythema. In practice, pruritus seemed related to burning; patients reported these events in the context of local discomfort. The incidence and intensity of these adverse events, particularly skin burning, decreased with time.

- Treatment with Tacrolimus is generally safe.
- No serious adverse events occurred that required treatment to be stopped.
- 0.1% Tacrolimus monotherapy have good Efficacy and Tolerability.

#### **DIRECTIONS FOR USE OF 0.1% TRACOLIMUS OINTMENT:**

- Apply as a thin layer to affected areas of your skin
- It may be used on most parts of the body, including the face and neck and in the creases of elbows and knees.
- Avoid using the ointment inside your nose or mouth or in your eyes. If the ointment gets on any of these areas, it should be thoroughly wiped off and rinsed off with water.
- Be sure your skin is completely dry.
- Patients were instructed to apply the medication 0.1% Tracolumus to the affected areas twice daily on dry skin.
- Patients were allowed unprotected (no sunscreen) natural sunlight exposure at midday: 5 minutes in the summer and 10 minutes in Winter and Spring.
- In a case study, the patient was developed with noticeable follicular repigmentation after 3 weeks of therapy and had complete repigmentation in 4 months.

#### **STORAGE:**

- Keep out of the sight and reach of Children.
- Do not use this medicine after the expiry date.
- Store at room temperature(15-25 deg.c)

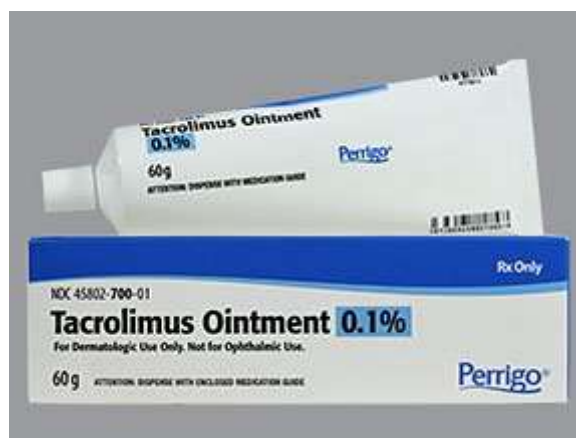

Image: Tacrolimus Ointment 0.1%

#### **EFFICACY:**

The greatest decrease in symptoms, as measured by the mEASI, was seen during the first week of treatment (Figure 2). The mEASI continued to decrease until month 3, and maximal improvement was maintained during the rest of the study. Decreases in affected body surface area showed the same trend over time (Figure 2). The size of the treated area over time was nearly identical

to the size of the affected area (data not shown). Ointment use also decreased; median daily ointment use was 3.9, 2.5, 2.0, and 2.3 g during months 1, 3, 6, and 12, respectively.

#### **TREATMENT:**

##### **MEDICATIONS:**

- Creams that control inflammation. Applying a corticosteroid cream to affected skin may help return color, particularly if you start using it early in the disease. You may not see a change in your skin's color for several months
- This type of cream is effective and easy to use. But it can cause side effects, such as skin thinning or the appearance of streaks or lines on your skin.
- Milder forms of the drug may be prescribed for children and for people who have large areas of discolored skin.
- Medications that affect the immune system. Ointments containing tacrolimus or pimecrolimus (calcineurin inhibitors) may be effective for people with small areas of depigmentation, especially on the face and neck.
- This treatment may have fewer side effects than corticosteroids and can be used with ultraviolet B (UVB) light. However, the Food and Drug Administration has warned about a possible link between these drugs and lymphoma and skin cancer.

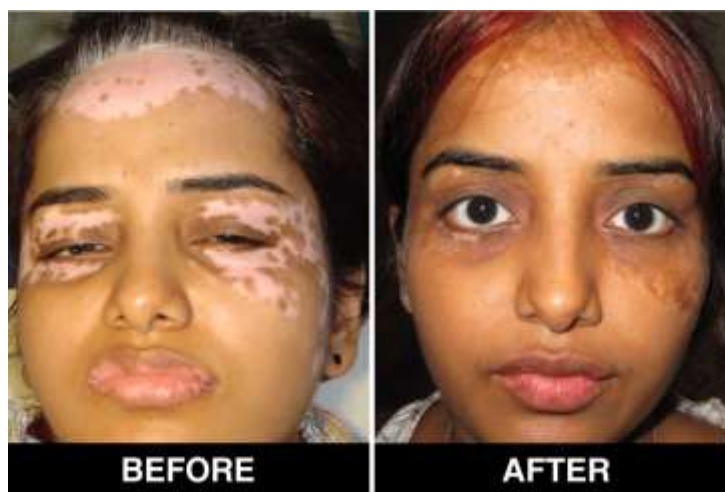

Image: Before treatment picture and after treatment picture

##### **SURGERY:**

Surgery may be an option for you if light therapy doesn't work. Surgery can also be used with those therapies. The goal of the following techniques is to even out your skin tone by restoring color.

- Skin grafting. In this procedure, your doctor removes very small sections of your normal, pigmented skin and attaches them to areas that have lost pigment. This procedure is sometimes used if you have small patches of vitiligo.
- Possible risks include infection, scarring, a cobblestone appearance, spotty color and failure of the area to recolor.
- Blister grafting. In this procedure, your doctor creates blisters on your pigmented skin, usually with suction. He or she then removes the tops of the blisters and transplants them to an area of discolored skin.
- Possible risks include scarring, a cobblestone appearance and failure of the area to recolor. And the skin damage caused by suctioning may trigger another patch of vitiligo.
- Tattooing (micropigmentation). In this technique, your doctor uses a special surgical instrument to implant pigment into your skin. It's most effective in and around the lips in people with darker complexions.
- Drawbacks include difficulty matching the skin color and potential for the tattooing to trigger another patch of vitiligo.

##### **POTENTIAL FUTURE TREATMENTS:**

- A drug to stimulate color-producing cells (melanocytes). Called Afamelanotide, this potential treatment is implanted under the skin to promote the growth of melanocytes.
- A drug that helps control melanocytes. Prostaglandin E2 is being tested as a way to restore skin color in people with localized vitiligo that isn't spreading. It's applied to the skin as a gel.
- A drug that reverses loss of color. Tofacitinib, an oral drug typically used to treat rheumatoid arthritis, has shown some potential as a treatment for vitiligo.

**DISCUSSION:** Long-term treatment is usually required based upon the clinical course of vitiligo; the ideal topical agent should have good clinical efficacy with a better safety profile. Topical tacrolimus is a topical calcineurin inhibitor derived from the bacteria *Streptomyces tsukubaensis*. Since 2002, several studies have shown this agent to have promising results in vitiligo. The response rates vary between 63% and 89% depending on the type and location of vitiligo, with good results for face and neck lesions.

**CONCLUSION:** The results of this study demonstrate that long-term treatment with tacrolimus ointment is safe and well tolerated in patients with moderate to severe atopic dermatitis. Local irritation seemed to be the only adverse event clearly



related to the use of tacrolimus ointment; no systemic toxic effects were apparent. Clinical improvement was apparent after 1 week of treatment, and maximal improvement was maintained with prolonged treatment. This agent represents a promising new treatment for atopic dermatitis.

#### REFERENCES:

1. Ortonne JP, Bahadoran P, Fitzpatrick TB, Mosher DB, Hori Y. Hypomelanoses and Hypermelanoses. In: Freedberg IM, Eisen AZ, Wolff K, Austen KF, Goldsmith LA, Katz SI, editors. *Fitzpatrick's Dermatology in Medicine*. 6th ed. New York: McGraw Hill; 2003.
2. Hamzavi I, Jain H, McLean D, Shapiro J, Zeng H, Lui H. Parametric modeling of narrowband UV-B phototherapy for vitiligo using a novel quantitative tool: The vitiligo area scoring index. *Arch Dermatol*. 2004.
3. Kanwar AJ, Dogra S, Parsad D. Topical tacrolimus for treatment of childhood vitiligo in Asians. *Clin Exp Dermatol*. 2004.
4. Lepe V, Moncada B, Caastanedo-Cazares JP, Torres-Alvarez MB, Ortiz CA, Torres-Rubalcava AB. A double-blind randomized trial of 0.1% tacrolimus vs 0.05% clobetasol for the treatment of childhood vitiligo. *Arch Dermatol*. 2003.
5. Kostovic K, Pasic A. New treatment modalities for vitiligo: Focus on topical immunomodulators. *Drugs*. 2005.
6. Silverberg NB, Lin P, Travis L, Farley-Li J, Mancini AJ, Wagner AM, et al. Tacrolimus ointment promotes repigmentation of vitiligo in children: A review of 57 cases. *J Am Acad Dermatol*. 2004.
7. Merk HRuzicka TedRing JedPrzybilla Bed Clinical symptoms of atopic dermatitis. *Handbook of Atopic Eczema*. Berlin, Germany Springer-Verlag1991;27- 30Google Scholar
8. Leung DYMHanifin JMCharlesworth EN et al. Disease management of atopic dermatitis: a practice parameter. *Ann Allergy Asthma Immunol*. 1997;79197- 211Google ScholarCrossref
9. Mukai HNoguchi TKamimura KNishioka KNishiyama S Significance of elevated serum LDH (lactate dehydrogenase) activity in atopic dermatitis. *J Dermatol*. 1990;17477- 481Google Scholar
10. Kapp A The role of eosinophils in the pathogenesis of atopic dermatitis: eosinophil granule proteins as markers of disease activity. *Allergy*.1993;481-5Google ScholarCrossref
11. Goto TKino THatanaka H et al. FK 506: historical perspectives. *Transplant Proc*. 1991;232713- 2717Google Scholar
12. Van Leent EGräber MThurston MWagenaar ASpuls PBos JEeffectiveness of the ascomycin macrolactam SDZ ASM 981 in the topical treatment of atopic dermatitis. *Arch Dermatol*. 1998;134805- 809