

Isolated Cor Triatriatum Sinistrum And Pregnancy: Case Report And Review Of The Literature

M. Bouslikhane, A.Assal, S.Ghdaif, A. Lamrissi, K. Fichtali, S. Bouhya

Maternity ward, Abderrahim Harouchi Children's Hospital Casablanca, Morocco.

Correspondent for the article: Doctor BOUSLIKHANE MEHDI

Address: 130 BOULEVARD ZERKTOUNI CASABLANCA

Telephone: +212 676 342 218

E-mail: mehdibouslikhane01@gmail.com

Abstract: A potentially serious congenital heart disease, triatrial heart is defined as a failure of the common pulmonary vein to connect to the left atrium during the early stages of embryogenesis. The anatomical consequence is the appearance of a fibrous membrane, occasionally muscular, which divides the left atrium into two very distinct chambers: a posterior proximal in connection with the pulmonary veins, called the pulmonary venous chamber, and a second distal anterior, close of the mitral valve where the left atrium is located, called the true left atrium. The frequency is rare, less than 0.1% of heart disease diagnosed clinically and 0.4% of congenital malformations recognized at autopsy.

We report a case of a triatrial heart accidentally discovered at the age of 28 WA whose decision was the induction of labor but the evolution was a non-reassuring fetal tracing thus indicating a cesarean section.

Keywords: Triatrial heart, pregnancy, prognosis, delivery route

Introduction

The isolated left triatrial heart (CTG) is a heart defect in which a membranep perforated fibromuscular divides the left atrium in halfbedrooms. When communication between these rooms is restricted, the patient may exhibit the signs and symptoms of mitral stenosis. At the end of pregnancy, we may observe tachycardia and increases in intravascular volume. We describe how this altered physiology could affect pregnant women with asymptomatic CTG. We also passreview the literature on pregnancy in patients with CTG.

Case description:

This is a 29-year-old patient mother of 3 living children all delivered vaginally, known to have a left triatrial heart at 28 weeks after a heart murmur discovered by chance by her referring doctor after a consultation for pulmonary infection. .

Examination of the patient found a patient in good general condition, normotensive at 12/6 cmHg, with a regular heart rate of 88 bpm. In terms of the heart, we find a systolic heart murmur rated 3 / 6th at the mitral focus, the rest of the examination is without anomaly. The patient's ECG is without abnormality (Figure 1).

Trans-thoracic cardiac ultrasound (TTE) revealed a membrane perforated by an orifice measuring 1.4 cm², dividing the left atrium into two compartments: Proximal, receiving the pulmonary and distal veins, continuing through the mitral valve orifice (figure 2). Blood circulating at a turbulent rate through the orifice of this accessory membrane. The mean mitral gradient was 1.56 mmHg for a mean mitral flow of 0.6 m / s. the maximum mitral gradient is 2.76 mmHg for a maximum flow of 0.86 m / s. In addition, no other cardiac abnormality was detected, the right atrium and the ventricles were without abnormality, the pulmonary arterial pressure was normal at 33mmhg with a systolic ejection fraction of 60%, there was no leak valve noticeable, overall cardiac contractibility was good, and the pericardium dry.

The pregnancy follow-up went without incident. The patient was not put on any medication related to her cardiac pathology and underwent another follow-up cardiac ultrasound at 36 WA which did not show any notable change from the assessment made 2 months earlier.

After multidisciplinary consultation: Obstetricians, cardiologists and resuscitators, the patient was initiated with misoprostol at 37 weeks without epidural analgesia beforehand but finally had to be caesarized for fetal tracing not reassuring at 2 h after its onset. The cesarean section was performed under spinal anesthesia without notable incident, giving birth to a newborn female, Apgar 10/10, with a birth weight of 2900g.

The parturient stayed in intensive care for one day postoperatively for monitoring, the postpartum cardiac evaluation (TTE - ECG) did not show any abnormalities and no cardiac symptoms appeared during the 3 days following childbirth. The patient was declared out on D3 with a cardiology follow-up letter.

Discussion

Triatrial pathologies are relatively rare, their incidence is in the order of 0.1 to 0.4% (series of autopsies) of congenital heart disease [1]

It results from a cardiogenesis disorder due to the defect in incorporation of the pulmonary vein common to the pulmonary circulation (cor triatriatum sinistrum) or defect in regression of the right horn of the right venous sinus (cor triatriatum dextrum). The triatrial pathology causes a pathological limited diastolic flow through the intra-auricular membrane equivalent to a mitral stenosis, the symptomatology depending on the surface of the membrane opening and may not point to congenital cardiac symptomatology [2,3].

From 10 weeks we observe an increase in metabolic requirements and circulating blood volume of up to 40 to 50% as the term approaches.

Cardiac output increases from week 8 and can be as high as 35-50% during the second trimester, resulting from increased heart rate and increased stroke volume secondary to the increase. blood volume.

The drop in systemic vascular resistance from the seventh week of amenorrhea is responsible for the drop in blood pressure [4], this context exposes more to the risks of dyspnea, pulmonary edema, and atrial fibrillation the latter constitutes a aggravating factor compromising the filling of the left ventricle. These changes are significant at 20-24 weeks, become more pronounced at term and explain the high frequency of cardiac decompensations observed in the peripartum [5].

The pathophysiology of CTS decompensation is similar to that of mitral stenosis. The main difference is that the obstructive site is at the level of the intra-auricular accessory membrane rather than at the level of the mitral valve. In mitral stenosis, the patient will be symptomatic when the area is reduced to less than 2 cm², to less than 1 cm² the risk of cardiac decompensation is critical. Increases in heart rate and intravascular volume in a patient with ACT, as in mitral stenosis, worsen cardiopulmonary signs and symptoms [6], thus the diastolic filling time is insufficient to fill the left ventricle and the pressure accumulates in the proximal left atrial chamber, resulting in pulmonary hypertension followed by pulmonary edema.

Secondary PAH is a turning point in ear disease. Often during triatrial pathology, the right ventricle is adapted to high levels of pulmonary arterial pressure, the challenge is therefore to avoid any sudden rise in PAH that can induce right ventricular failure. [7], the proportion of cardiac decompensations is more pronounced in a preeclamptic parturient due to an increase in pulmonary capillary permeability; [6].

Thus, the signs and symptoms of preeclampsia should be treated and detected early, more aggressive treatment should be undertaken in these patients. It should be noted that our patient remained asymptomatic despite the pregnancy -induced changes in cardiovascular dynamics, as evidenced by the increase in the diastolic pressure gradient.

Bojavic et al in 2013 [7] identified in a review of the literature on a series of 13 patients with a triatrial heart discovered during pregnancy, out of the thirteen patients 3 were diagnosed symptomatic following a heart murmur the rest of the patients were asymptomatic at diagnosis but became so during their monitoring during pregnancy.

Changes in cardiac workload during pregnancy are generally well tolerated by the right heart, this may not be the case for an obstructed heart, especially in cases of CTS in which the probability of becoming symptomatic increases as early as 20 weeks. This likelihood is even greater during childbirth and the postpartum period. Thus, the early identification of all asymptomatic patients with CTS begins by giving importance to each so-called "innocent" breath during pregnancy.

To avoid CTS decompensation, consideration should be given to correcting the obstacle before pregnancy and considered that the patient is at high cardiac risk throughout her pregnancy.

Any cardiac sign, even those frequently observed during a normal pregnancy: palpitation, shortness of breath, irregular heart beat, take on all its magnitude in the event of a triatrial sinistrum heart and could suggest cardiac decompensation. In addition, it is possible to be asymptomatic during pregnancy and become so during a subsequent pregnancy, and this is all the more true in cases of preeclampsia.

The aim of medical treatment is to lower the heart rate, for this beta blockers and diuretics are used if atrial fibrillation sets in, anticoagulant products will be prepared to mitigate the risk of thromboembolism [8]. Surgery will be offered in the event of the onset of acute heart failure or severe pulmonary arterial hypertension [9]. The open-heart surgical approach using cardiopulmonary bypass surgery is preferable to percutaneous procedures rarely used for this type of pathology.

If emergency surgery is indicated during pregnancy, anesthesia should follow the same hemodynamic rule as those established for intraoperative ECP of mitral stenosis (avoid tachycardia, maintain blood volume, avoid hypo TA by lateral tilt) avoid the increase in pulmonary arterial resistance due to hypercapnia and certain drugs [10]. Although there is no series in the literature on obstetric anesthesia for triatrial heart disease, cases of cesarean sections under general or locoregional anesthesia have been reported. Bonnin et al. [11] reported a retrospective series of 15 pregnancies in 14 patients with PAH over a ten-year period. The impact of the anesthesia technique appeared modest, as mortality was 20% in patients who had a cesarean section under combined peri-spinal anesthesia versus 25% under general anesthesia. These figures are close to those reported in parturients with PAH with a mortality of 30 to 50% [12] and a risk of death which remains high within ten days postpartum.

In our case, a spinal anesthesia appeared to us more suitable because of the absence of cardiac repercussions of the triatrial heart, in this case the paucisymptomatology of the patient: absence of orthopnea in the patient and the absence of signs in favor of right heart failure as well as the absence of pulmonary arterial hypertension.

Conclusion

Successful cardiac operations requiring CPB have been reported during pregnancy, but experience is still limited. In this parturient undergoing repair of cor triatriatum, successful perioperative management included prevention of tachycardia, atrial

dysrhythmias, and pulmonary hypertension, close monitoring for and prompt treatment of maternal hypotension, high CPB index, and avoidance of hemodilution and hypothermia. These strategies, as well as minimizing aortic cross clamp and CPB time, were used with successful maternal and fetal outcomes.

"Conflict of interest: none"

References :

- 1- Jegier W, Gibbons JE, Wiglesworth FW. Cor triatriatum: clinical, hemodynamic and pathological studies surgical correction in early life. *Pediatrics* 1963; 31:255–67.
- 2- Yeomans ER, Gilstrap 3rd LC. Physiologic changes in pregnancy and their impact on critical care. *Crit Care Med* 2005;33(10 Suppl.):S256–8
- 3- Y. Gavand , M. Krausz-Grignard , B. Barrucand, L. Courtois , E. Samain. Anaesthesia for caesarean section in a pregnant woman with cor triatriatum. *Annales Françaises d'Anesthésie et de Réanimation* 30 (2011) 688–691
- 4- literature Katarina Bojanic, Danijel Bursac, Jasenka Zmijanac, eljko Duic, Federica Scavonetto, Toby N. Weingarten, Juraj Sprung, *Can J Anesth/J Can Isolated cor triatriatum sinistrum and pregnancy: case report and review of the Anesth* (2013) 60:577–583
- 5- Robson SC, Hunter S, Moore M, Dunlop W. Haemodynamic changes during the puerperium: a Doppler and M-mode echocardiographic study. *Br J Obstet Gynaecol* 1987;94:1028–39
- 6- Humpl T, Reineker K, Manlhiot C, Dipchand AI, Coles JG, McCrindle BW. Cor triatriatum sinistrum in childhood. A single institution's experience. *Can J Cardiol* 2010; 26: 371-6
- 7- Loeffler E. Unusual malformation of the left atrium: pulmonary sinus. *Arch Pathol (Chic)* 1949; 48: 371-6
- 8- Wallace A. Cardiovascular disease. In: Stoelting RK, Miller RD, editors. *Basics of Anesthesia*. 5th ed. Philadelphia: Churchill Livingstone; 2007. p. 365-92.
- 9- Bonnin M, Mercier FJ, Sitbon O, Roger-Christoph S, Jais X, Humbert M, et al. Severe pulmonary hypertension during pregnancy: mode of delivery and anaesthetic management of 15 consecutive cases. *Anesthesiology* 2005; 102:1133–7.
- 10- Task force on the management of cardiovascular diseases during pregnancy of the European Society of Cardiology. Expert consensus document on management of cardiovascular diseases during pregnancy. *Eur Heart J* 2003;24:761–81.
- 11- Sajeev CG, Roy TN, Krishnan MN, Venugopal K. A case of cor triatriatum diagnosed during pregnancy. *Int J Cardiol* 2003; 90: 127-8. 13.
- 12- Takeuchi Y, Kurogane K, Nishimura Y, Kajiura T, Nakata H. Asymptomatic cor triatriatum in an elderly patient: observation by biplanar transesophageal Doppler echocardiography. *Jpn Circ J* 1997; 61: 189-91.

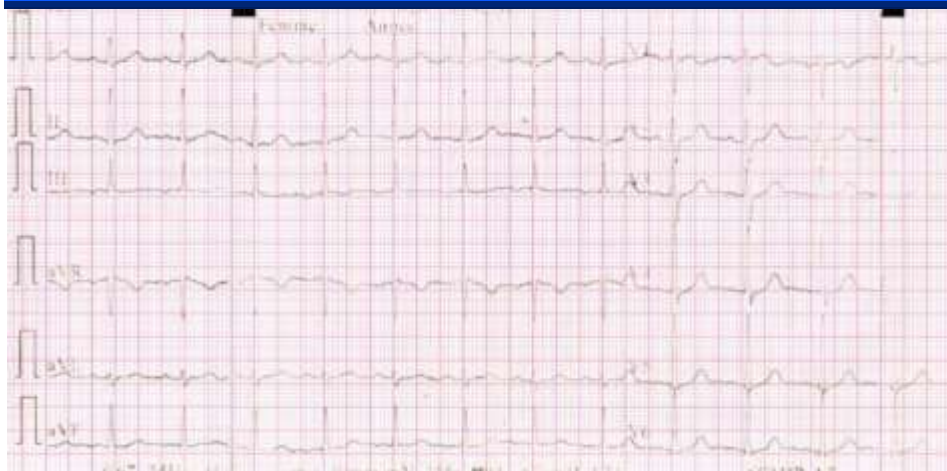

Figure 1 : ECG shows no significant ch

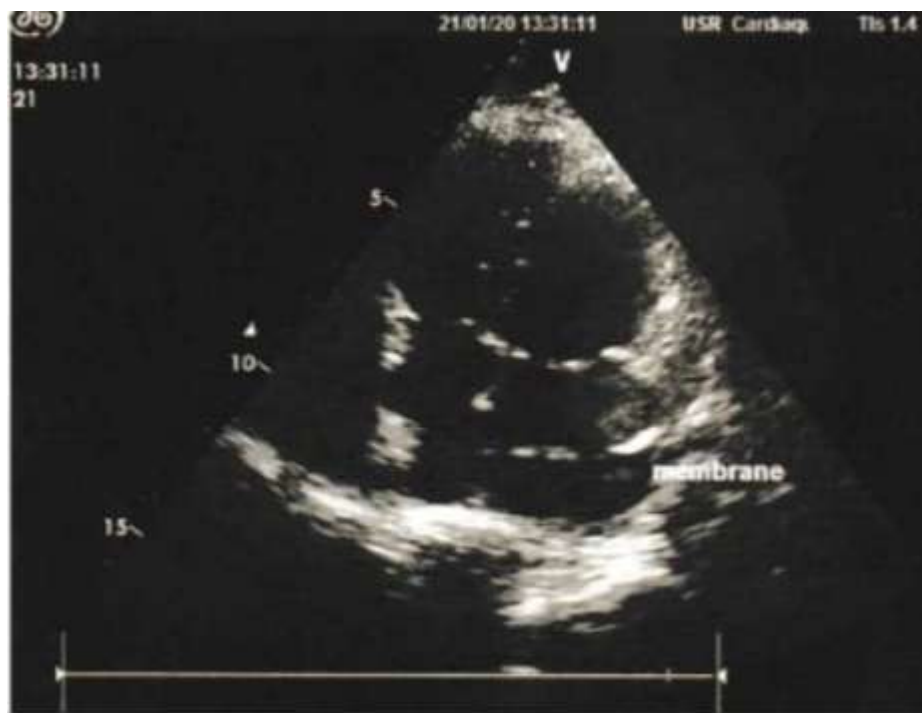

Figure 2: Image échocardiographique montrant une membrane non obstructive séparant l'oreillette gauche en deux parties inégales.

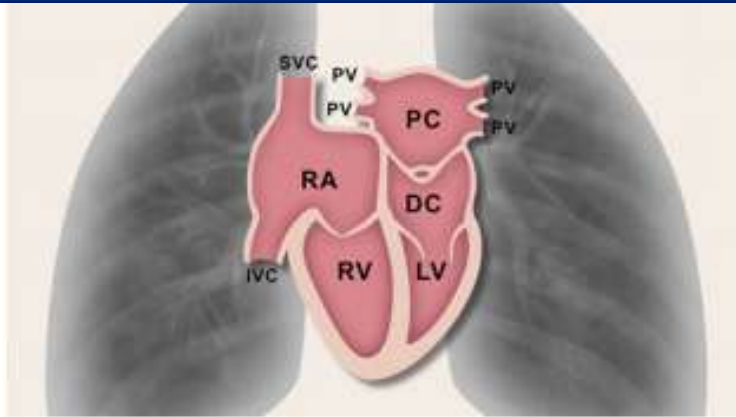


Figure 3: Illustration of isolated form of cor triatriatum sinistrum. Left atrium is divided with interatrial membrane into proximal chamber (PC) and distal chamber (DC), and the blood flow occurs via a single opening in the membrane. IVC = inferior vena cava; LV = left ventricle; PV = pulmonary vein; RA = right atrium; RV = right ventricle; SVC = superior vena cava.