

# Hydrocele Stone with Its Composition Analysis about Two Cases Report with Literature Review

Abdennasser LAKRABTI <sup>1,2</sup>, Ali AKJAY <sup>1,2</sup>, Khalid LEMAZQUIDI <sup>2</sup>, Abdeghani AMMANI <sup>1,2</sup>, Jihad ANZAOU <sup>1,2</sup>

1: Faculty of Medicine and Pharmacy, Sidi Mohammed Ben Abdallah University, BP: 1893, road Sidi Harazem, 30070 Fez, Morocco .

2: Urology Department, moulay Ismail military hospital , 50000 Meknes , Morocco

Corresponding author: Abdennasser LAKRABTI

E-mail address: [lakrabinasser@gmail.com](mailto:lakrabinasser@gmail.com)

Phone number: +212 701219909

**Abstract:** “Scrotal pearl” or hydrocele stone correspond to the presence of freely floating or located calcifications lying between the layers of the tunica vaginalis of the testes, and have been reported very briefly in the literature, we present here two cases of hydrocele stone are found during an operation. Our aim is discuss the etiology and composition analysis of hydrocele stones.

**Keywords:** composition analysis, stone, hydrocele, calculus, Scrotal, pearl.

## ◆ Introduction

Scrotal calculi correspond to the presence of freely floating or located calcifications lying between the layers of the tunica vaginalis of the testes [1–3]. In the hydrocele fluid, scrotal calculi are found incidentally during ultrasound, operation, or clinical if large, and have been mentioned very briefly in the literature we hereby present the cases and discuss the etiology and Composition analysis of hydrocele stones.

## Cases Presentation

### ➤ Case report 1

A 30-year-old man unmarried, with a history of unprotected sexual activity, but without sexually transmitted diseases, presented with sudden left scrotal pain. He had a history of intermittent left scrotal pain since four years without fever, urinary signs or urethral discharge.

Physical examination of the patient revealed a normal scrotum, pain on left testicular mobilization without other clinical signs of testicular torsion, biological parameters were normal including CRP and white blood cells; the patient is sent to the operating room for suspected testicular torsion.

After incising the tunica vaginalis ,left testes and epididymis were anatomically unremarkable, not indicating previous infection or trauma, and three stones were found , that was not attached to the tunica vaginalis testis .their sizes measured 11 mm, 6 mm and 2 mm respectively([figure 1 and 2](#)), a plicature of the tunica vaginalis was made , the patient recovered well and the post-operative period was uneventful. Infrared spectrophotometric analysis shows that the stones are composed of three components: the peripheral layer is made up of a rate of carbapatite, which is higher than that of whitlockite and proteins, while the central layer is composed of 60% of whitlockite, 20% of carbapatite, and 15% of proteins.

### ✓ Case report 2

A 60 years old patient, having a diabetes mellitus under oral antidiabetic drugs, who

Consulted for chronic and painful large bursa for 2 years, at the physical examination is

normal except for a left bursa which is increased in volume without being able to palpate the

Left testicle, the biological parameters were normal, in particular the white blood cells and

The CRP, at the ultrasound scan left hydrocele of great abundance, unfortunately without

Visualization of the hydrocele calculus, intraoperatively a whitish mobile calculus was discovered (figure 3) measuring 6 mm in its long axis that was not attached to the tunica vaginalis testis, its spectrophotometric analysis at the infrared showed: 60% of carbapatite, 38% of whitlockite, and 2% of proteins, with a carbonation rate of 27%.

◆ **Discussion :**

In 1935, during an operation, Kickham was the first to describe intrascrotal calculus as a “fibrinoid loose body” or “scrotal pearl” [1-2]. It is a rare discovery with a reported incidence ranging between 1.5% and 3% [4, 5], in the formation of an intrascrotal calculus, two mechanisms are discussed. [2] These are the torsion of the appendix testis or epididymis. [2] and the inflammation of tunica vaginalis testis, the first mechanism is unlikely since there are multiple calculations in our first case, The second mechanism of IC formation seems to be clearer in explaining the origin of these stones. According to this theory, the formation of an Intrascrotal Calculus can be as follows: the endothelial cells of the tunica vaginalis of the testis exfoliate, resulting in bleeding with fibrin deposition on the tunica vaginalis, and then this deposit forms a nidus. This nidus eventually calcifies to form an intrascrotal stone [2, 6].

Etiology for hydrocele stones is unknown. Preceding hematoma, trauma, infection as it reported bay Hussein et al mention parasites, especially filarial worms, as one of the causes of calculi in hydroceles [7] , or torsion of appendix epididymis or appendix testis are suspected [8], but past history of that kind was not indicated in the present cases.

some studies revealed the prevalence of scrotal calculi was very high in some specific populations. Frauscher et al. [9] reported that the prevalence of scrotal calculi was 81 % in mountain bikers. Namjoshi [10] reported that the incidence of scrotal calculi was 4.3 % and would rise to 9 % if calcareous material was added , the high prevalence in these two studies may be partially due to the population selected, also the Introduction of ultrasound has led to increase in diagnosis of this rare entity with high frequency transducer ultrasonography. This investigation of choice showing the movement of hyperechoic lesion in the fluid between the tunica, with discrete acoustic shadow. [2, 9, 10]

To the best of our knowledge, scrotal calculi without hydrocele have not been previously reported , so ,our first case is the only that reports multiple calculations without associated hydrocele, The reports indicating crystallography of calculi in hydrocele showed that stones compositions : hydroxyapatite in the core surrounded by organic matters [11] , and another stone which was big (8.7 cm) in size was composed of magnesium ammonium phosphate [12] ,a white smooth stone of 11mm in diameter ,and the hydrocele stone was of yellow hard center with white materials around it. Crystallographical analysis by an infrared spectrophotometer showed that the center was composed of 64% calcium carbonate and 36% calcium phosphate, while the outer portion was protein [13] , two other cases of scrotal calculus, one was white and other was brown and their composition revealed 100% carbonate apatite[14].

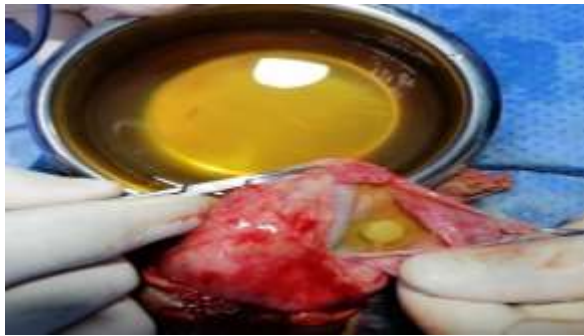
Intrascrotal calculus is a benign disease; the Accumulation of such data must be significant in order to delineate the etiology of the disease.

◆ **CONCLUSION**

Calculus in hydrocele does not change the management or prognosis, if the stone is adherent to the tunica and does not change position on ultrasonography, there is a possibility of a tumor which should be kept in mind.



**Figure 1.** Size of hydrocele stones  
White hydrocele stones



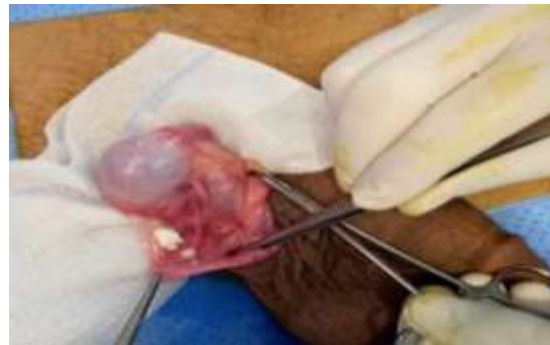**Figure 3.** White hydrocele stone

#### Declaration of interest statement

There are no conflicts of interest.

#### References

1. Kickham CT. Calcified hydrocele of the tunica vaginalis testis: Case report. N Engl J Med 1935;212:419.
2. Linkowski GD, Avellone A, Gooding GA. Scrotal calculi: Sonographic detection. Radiology 1985;156:484.
3. Khanna S, Ticckoo S. Calculous disease in hydrocele. Eur. Urol. 1989;16: 235–6.
4. Artas H, Orhan I. Scrotal calculi. J Ultrasound Med 2007;26:1775-9.
5. Tan S, Özcan MF, Karaoğlanoğlu M, Ipek A, Özcan AS, Arslan H. Prevalence of scrotal calculi and their relationship with pain. Diagn Interv Radiol 2012;18:303-6.
6. Spence LD, Moran V. Ultrasound of intrascrotal calculi. Eur. J. Radiol. 1995;20: 210–11.
7. Hussein O, El Setouhy M, Ahmed ES, et al. Duplex Doppler sonographic assessment of the effects of diethylcarbamazine and albendazole therapy on adult filarial worms and adjacent host tissues in Bancroftian filariasis. Am J Trop Med Hyg 2004;71:471-7.



**Figure 2.**

8. Frauscher F, Klauser A, Stenzl A, Helweg G, Amort B. US findings in the scrotum of extreme mountain bikers. *Radiology* 2001; 219: 427–31.
9. Namjoshi SP. Calculi in hydroceles: sonographic diagnosis and significance. *J Clin Ultrasound* 1997; 25: 437–41.
10. J. M. Sánchez Merino, A. Lancina Martín, and G. F. Freixedas. Intrascrotal lithiasis. Crystallographic analysis. *Archivos Españoles de Urología*, vol. 55, pp. 523–526, 2002.
11. G.-H. Li, X.-D. Li, S. Cheng, and Z.-D. Chen. A large intrascrotal calculus. *Asian Journal of Andrology*, 2005, vol. 7, no. 1 : 103–105.
12. Masayoshi Zaitu, Koji Mikami, Yuta Takeshima, and Takumi Takeuchi. A Case of Hydrocele Stone with Its Composition Analysis. *Case Reports in Medicine*. Volume 2010, Article ID 586204, 2 pages.
13. Winfried Vahlensieck, Albrecht Hesse. Calculi in Hydrocele: Incidence and Results of Infrared Spectroscopy Analysis : Case Report . *Korean J Urol* 2010;51:362-4.